



Dossier 7

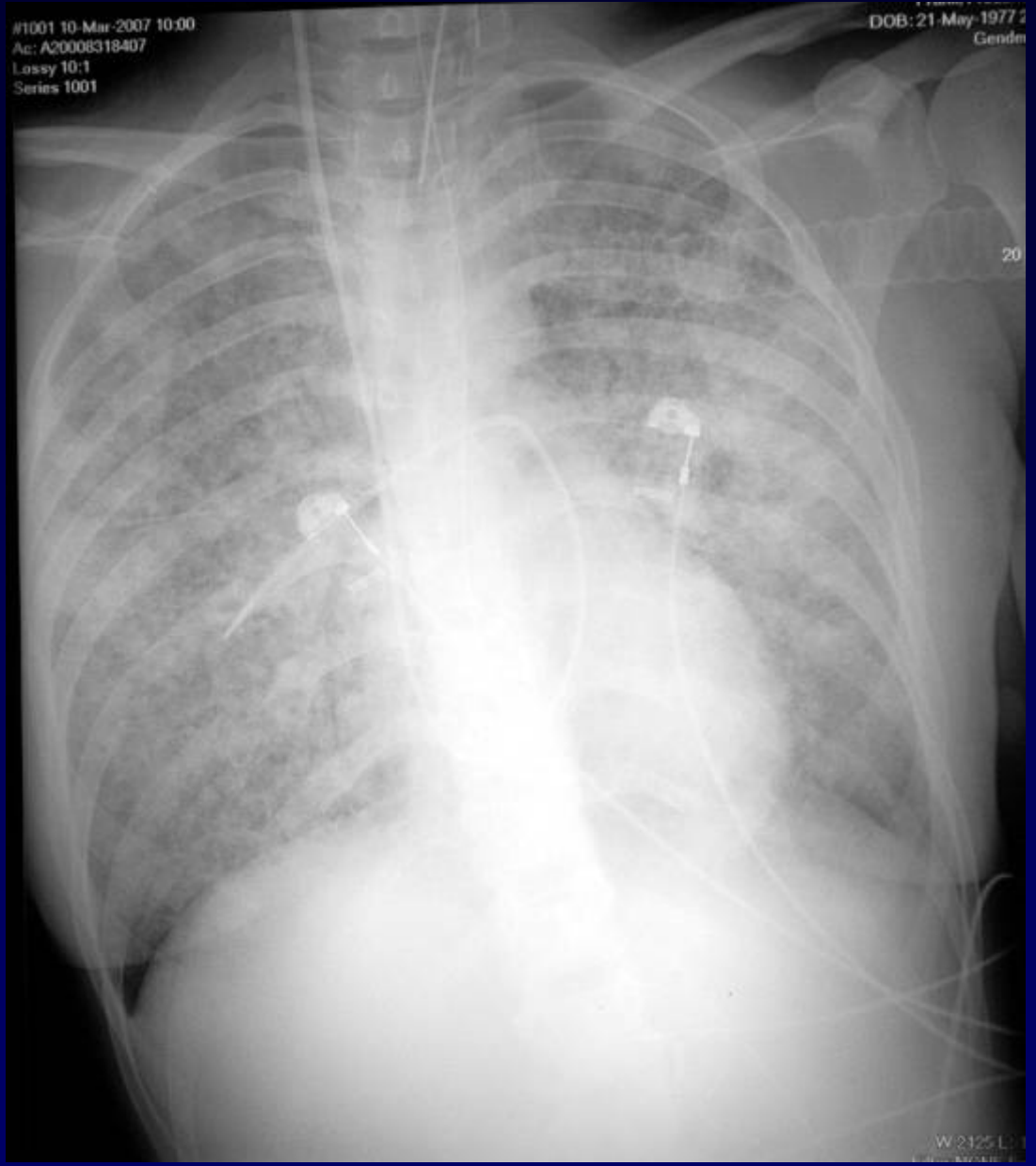
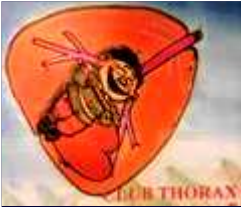**J GIRON
P FAJADET**

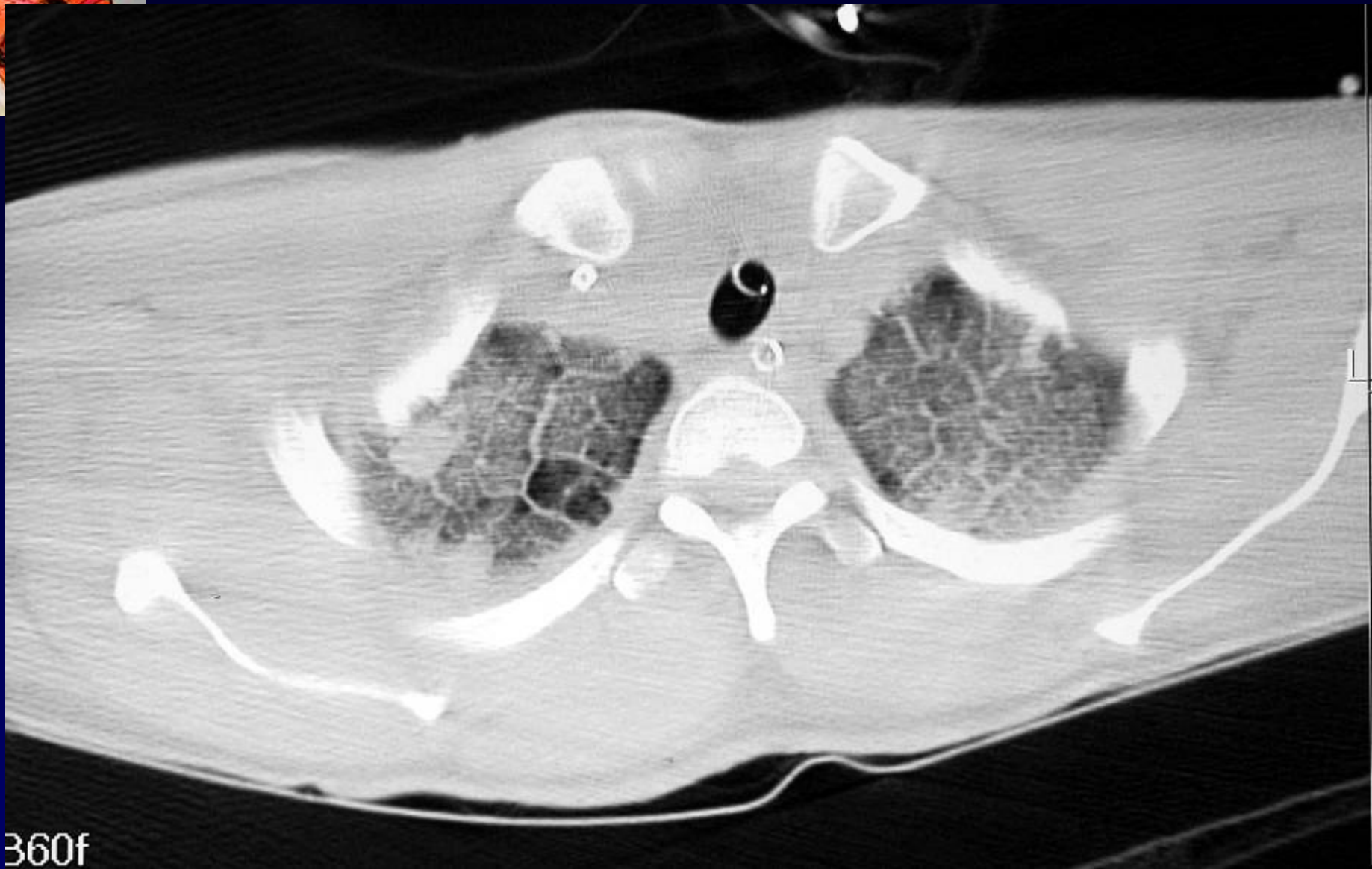
Femme de 29 ans

En bonne santé jusque là...

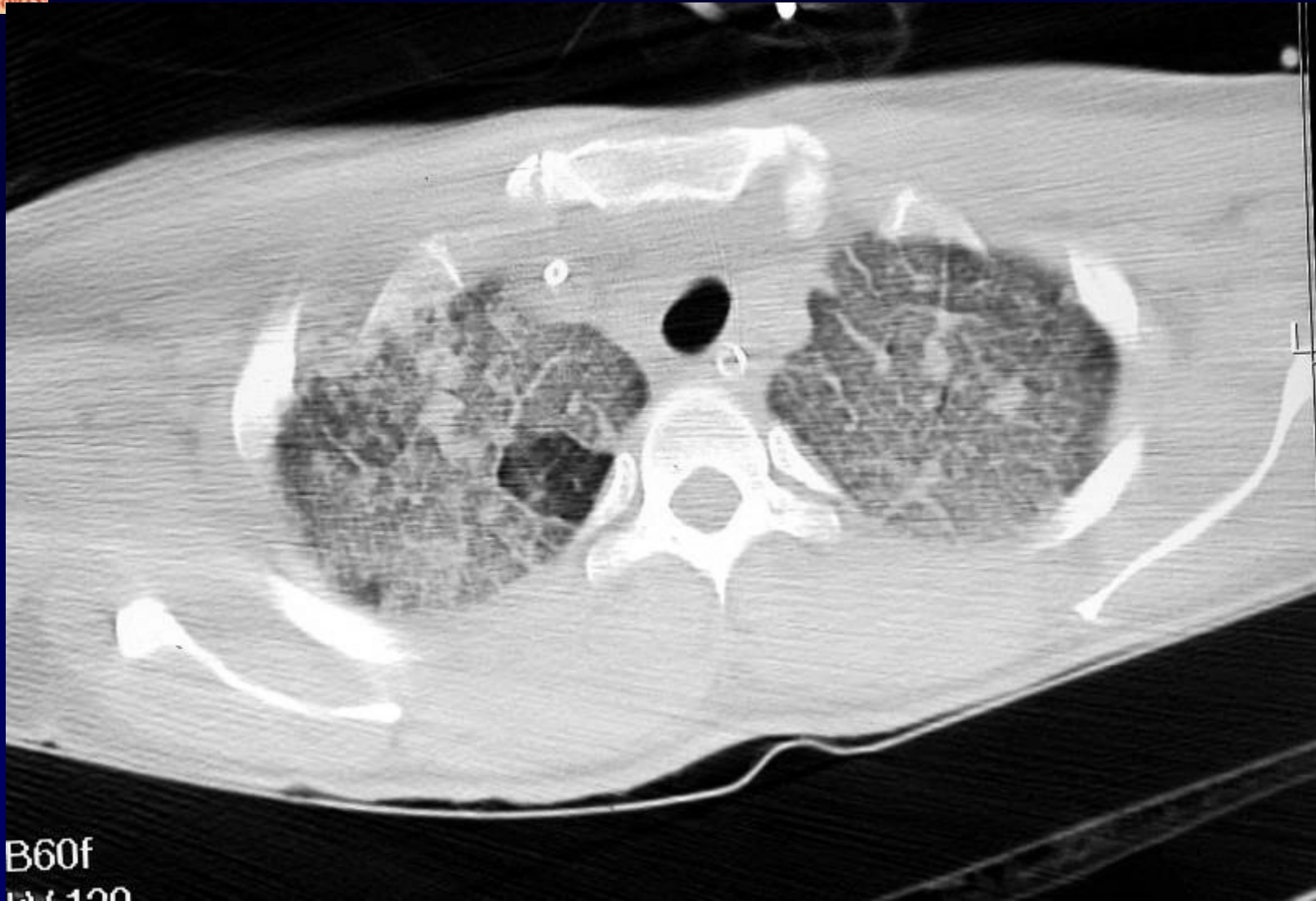
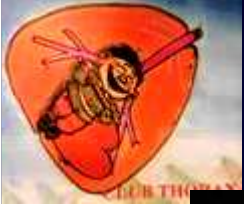Dégradation brutale de l'état respiratoire

Radio thorax et TDM

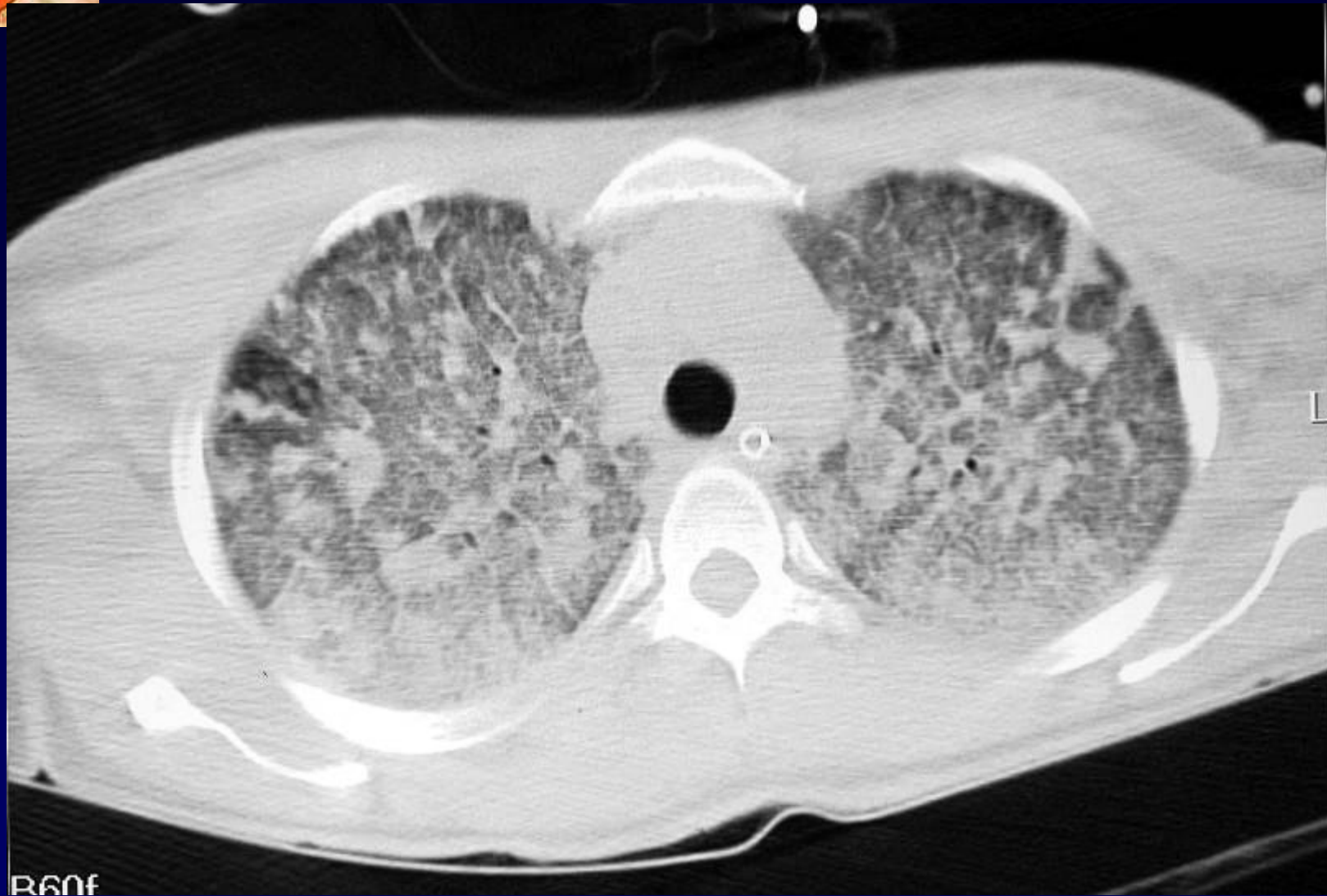
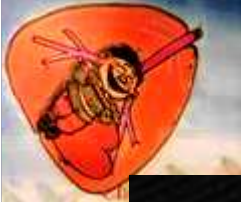


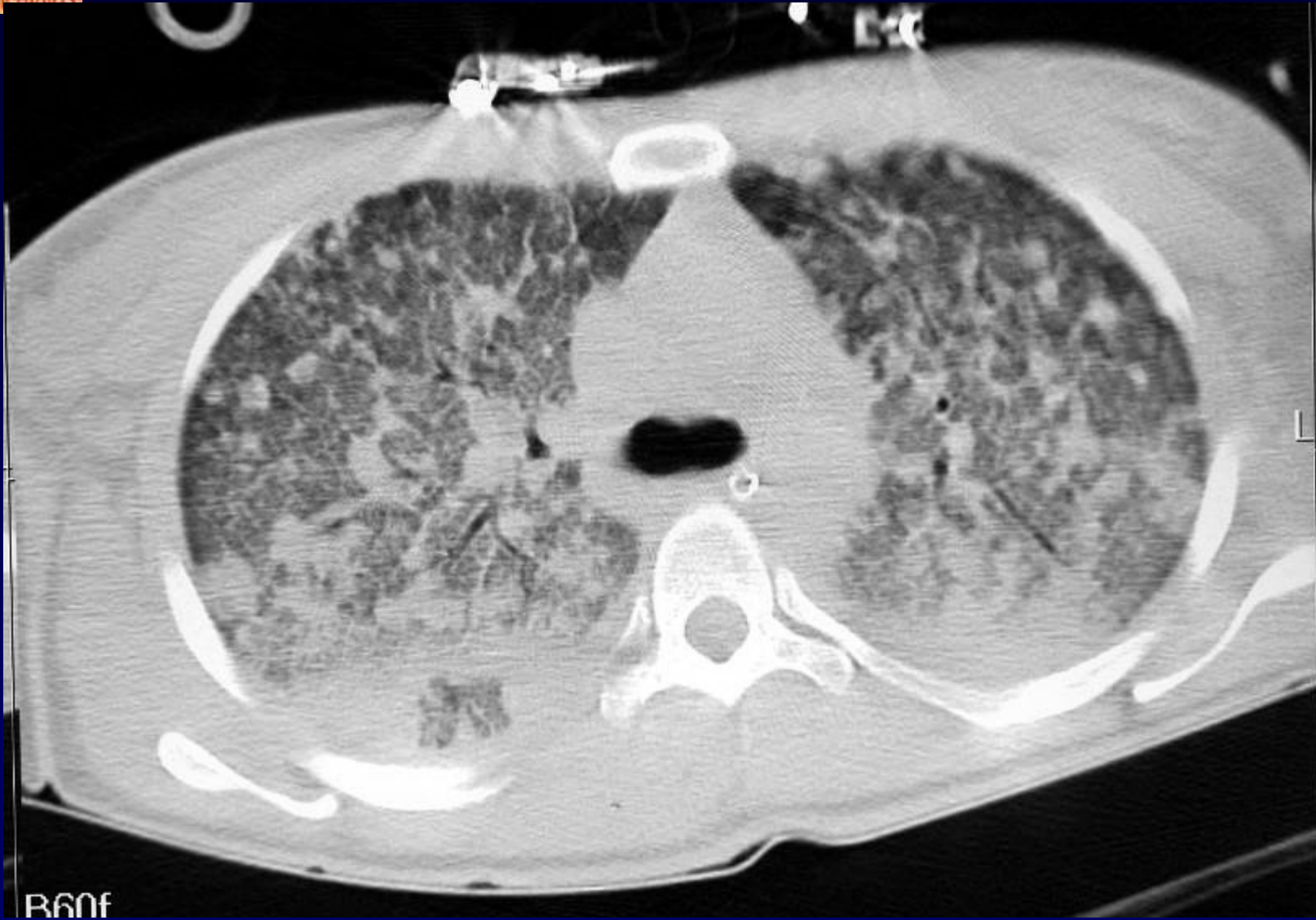
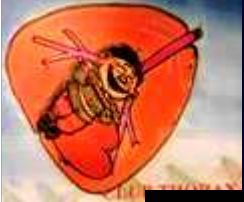360f

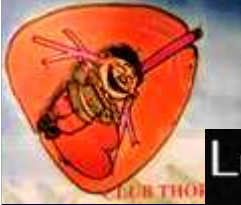

B60f
11/100



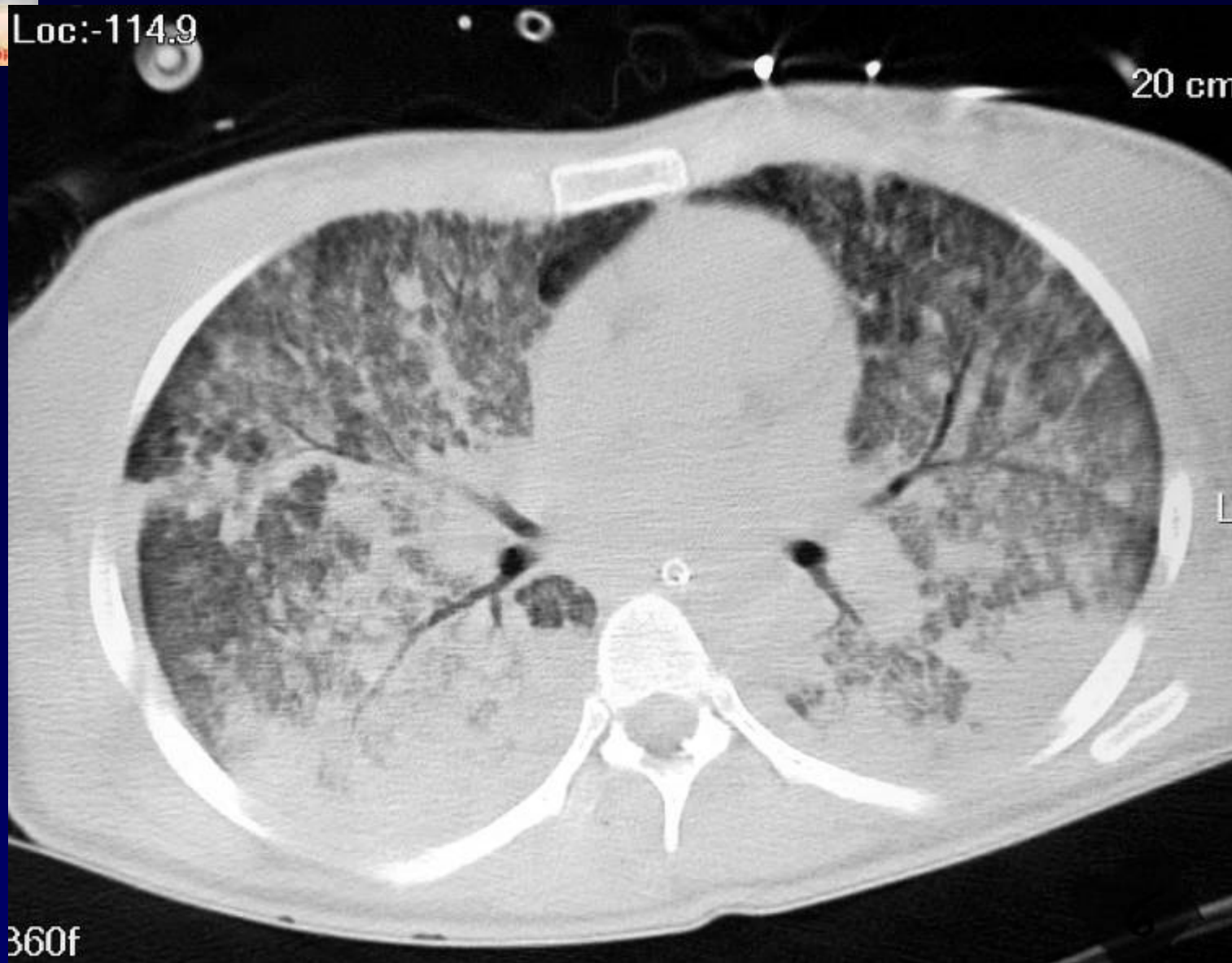
R60f





Loc:-114.9

20 cm



360f

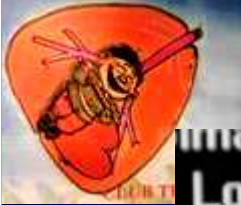
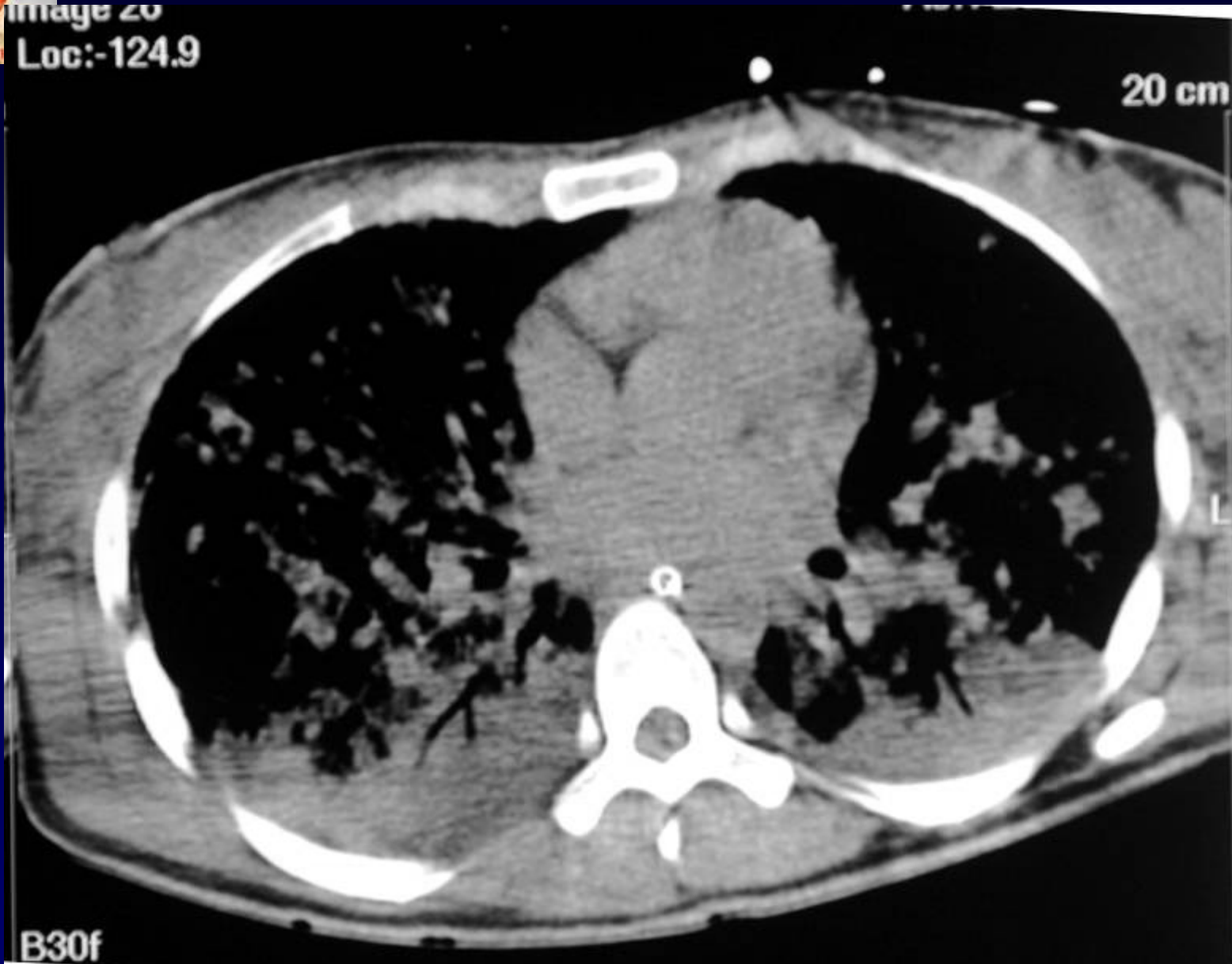
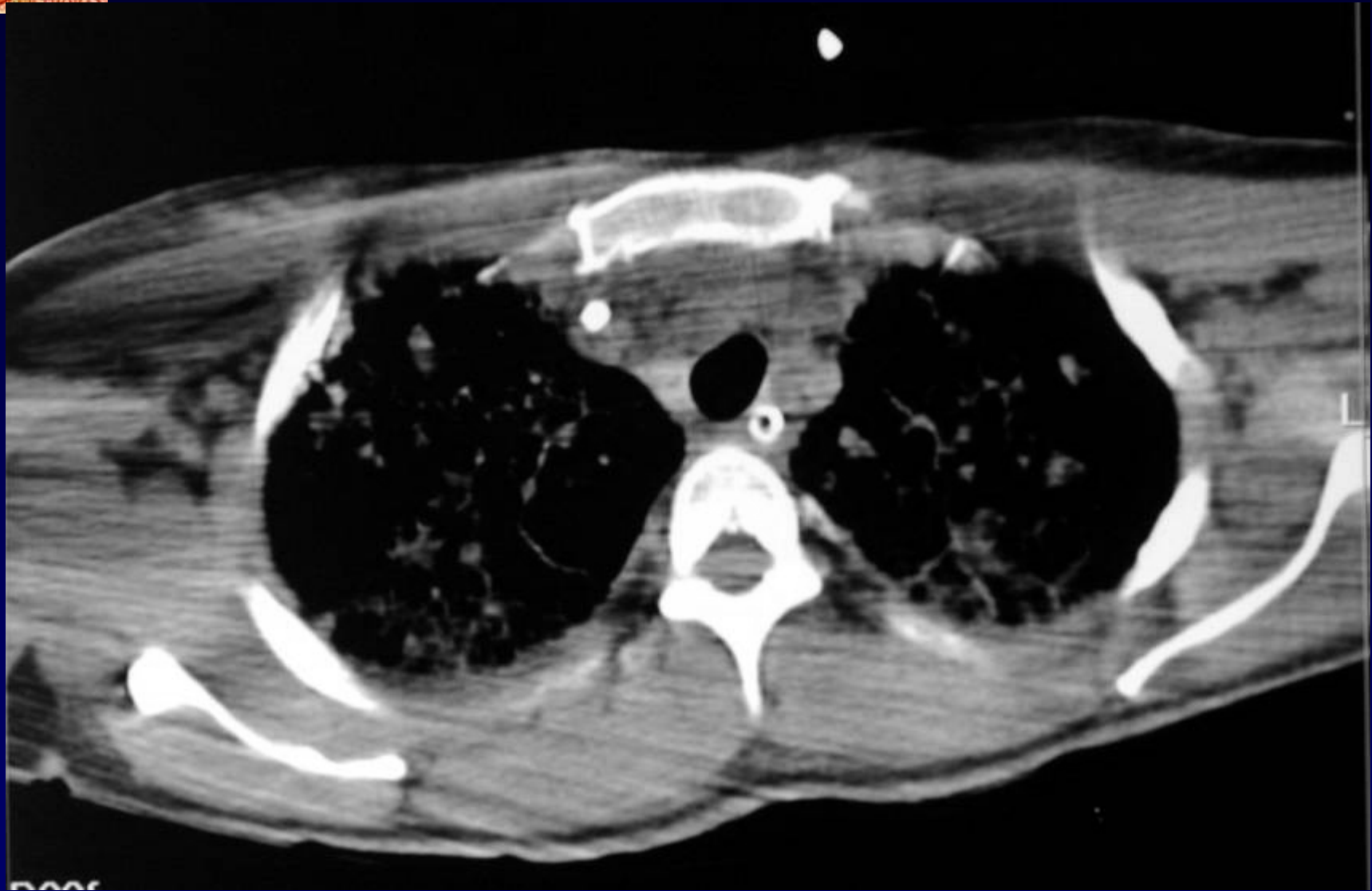
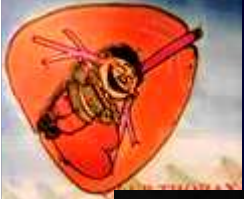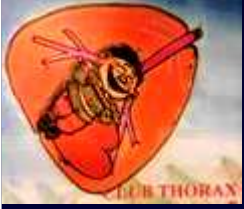Image 20
Loc:-124.9



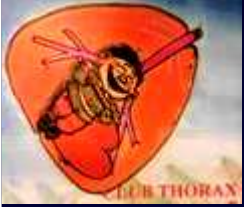20 cm

B30f





Diagnostic ?



Examen clinique :

Macules hémorragiques sur la peau....



Diagnostic ?



Diagnostic

VARICELLE MALIGNE

Codage : Poumon - Infectieux